

# Fish Bone Dislodged from the Throat Stuck in the Rectum: Case report

QUAZI MANJURUL HAQUE<sup>1</sup>, AHMED EID ALHARBI<sup>1</sup>,  
SALMAN ALJUBORI<sup>2</sup>, FATMA SALMAN<sup>2</sup>, MOHAMMED  
ASHRAF SALEM<sup>3</sup>, MUSHABBIR HOSSAIN<sup>3</sup>

<sup>1</sup>Department of Microbiology and Immunology, College of Medicine, Taibah University, Madinah, Saudi Arabia; <sup>2</sup>Department of Surgery, Al Ansar Hospital, Madinah, Saudi Arabia; <sup>3</sup>Department of General and Acute Medicine, Al Ansar Hospital, Madinah, Saudi Arabia

Received 22 November 2016

Accepted 17 January 2017

## Introduction

Many people have the experience in life having a fishbone stuck in his throat. It is something that happens when fish or meat is ingested that still have some of its smaller bones are present in it. When this happens, usually we have to wait for the bone to dislodge itself or we eat or drink other things, to dislodge or remove it from the throat. In some cases people might go to the doctor to remove it.

After removal from the throat it passes through the GIT and mostly removed from the body with stool. But in some cases it may stick once again at any part of the GIT especially if the bone has multiple spikes [1]. There are multiple case reports describing perforation and penetration of various internal organs and rectum by fish bone [2, 3].

## Case Report

A 52-years-old male medical personnel presented to the surgical outpatient clinic of Al-Ansar Hospital, Madinah, Saudi Arabia with a complaint of severe stabbing anal pain of three hours duration. He informed that 6 days back a fishbone stuck in his throat while he ingested fish in his lunch. He felt severe pain and spasm in the throat.

Correspondence to: Dr. Quazi Manjurul Haque

Email: quazi98@hotmail.com

## ABSTRACT

**Background:** An ingested fish bone stuck in the throat is not much uncommon in daily life. It could either be harmless or harmful. In most case it passes down through the gastrointestinal tract (GIT) by the peristaltic movements. As a sharp object, it can be dangerous causing perforation of the GIT and surrounding organs including the lungs, heart, liver and spleen.

There are multiple case reports describing perforation and penetration of various internal organs and rectum by fish bone.

**Case report:** Here we report a case of fishbone stuck in the throat when the patient accidentally swallowed a fish bone; the bone was dislodged after few minutes by home remedy as he swallowed some sticky rice balls. The patient felt severe abdominal pain for 2-3 hour on the 4th day. On the 6th day he had severe anal pain. He went to the emergency department and the doctor tried to remove the bone per rectally by finger. Finally it was removed manually under spinal anesthesia.

**Conclusions:** There are different home remedies for the sticking of fish bones in the throat. But when it sticks or penetrate the wall of GIT surgical manipulation may be needed

## KEY WORDS:

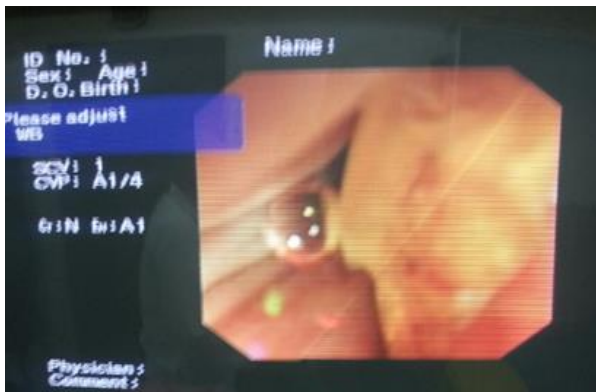
Fish bone  
Throat  
Rectum  
Foreign body  
Anorectal junction

Immediately after that he swallowed few soft and sticky rice balls and had a glass of water as well. He felt that the bone has dislodged after few minutes and it caused relief of pain and spasm in the throat. Three days later he felt severe pain in the umbilical region for 2-3 hours and eventually the pain got relieved without any medication. On the sixth day after a defecation he started to feel stabbing pain in the anal region and rushed to emergency department of the hospital. He was very anxious and distressed.

The surgical consultant felt some pointed foreign body by per rectal examination (PR) and tried to remove manually with the patient at different positions. This approach failed.

Nothing was visible by proctoscopy. An X-ray of the lower abdomen and pelvis was done but revealed nothing abnormal clearly but a suspicion of foreign body near the shadow of the coccyx. As the patient compliant of severe pain, the surgeon sent him to gastro-enterology department for sigmoidoscopy. In sigmoidoscopy, however, revealed a piece of bone lying transversely across the rectum just above the anorectal junction; two ends of the bone were embedded in the wall (Figure 1). No abnormality was found on general physical examination and routine lab investigations of the patient.

**Figure 1.** Fish bone embedded in the rectal wall.



Decision was made to remove the foreign body per rectally under spinal anesthesia. The patient was placed in lithotomy position. After dilatation of the anal sphincter manually the piece of bone was identified and mobilized by finger and finally removed. There was some bleeding from the area of bone embedded. An anal gauze-pack was inserted after removal of the bone to prevent bleeding. A prophylactic Metronidazole was prescribed. The patient was admitted for observation overnight and discharged next day without residual problems.

**Figure 2.** Fish bone after removal from the rectal wall



## Discussion

Accidental fish bone swallowing is a common occurrence as fish is a regular part of human meal, bone ingestion turned out to be an inevitable associated risk on the daily eating activities [4]. Goh et.al revealed that fish bone was the commonest type of foreign body (FB) ingested [5].

Most ingested foreign bodies pass through the GIT uneventfully within 1 week; however, owing to the bone sharpness, it may potentially cause penetration or perforation of GIT and vital internal organs. The patient felt pain in the umbilical region on the 4th day which could be due to the sticking of the bone in the GIT wall, especially, in the ileocecal junction. After that it might had a successful and harmless passage in the GIT and again lodged and stuck just above the anorectal junction. Usually, foreign bodies become lodged in the mid rectum, where they cannot negotiate the anterior angulations of the rectum. They can be felt on digital examination. With adequate sedation, most rectal FBs can be extracted transanally either in the emergency department or operation theater under direct vision [6]. If the foreign object is palpable and can be visualized; a local anesthetic agent is given by subcutaneous and submucosal injections of 0.5% lidocaine. The anus can be dilated with a rectal retractor and the foreign body grasped and removed. Removal of a rectal foreign body may be of high risk and should be done by a surgeon or gastroenterologist skilled in foreign body removal. Abdominal examination and chest X-rays may be necessary to exclude possible intraperitoneal rectal perforation. Sigmoidoscopy is required following extraction to evaluate mucosal injury or perforation [7]. Operative intervention is needed in minority of the patients who developed signs of perforations, peritonitis, bleeding, obstruction, and pelvic sepsis [6]. Possible intervention could include a proctoscopy, sigmoidoscopy retrieval of rectal FBs, or laparotomy with subsequent stoma, closure of perforation or Hartman's procedure. The reported patient was fully aware of the presence of the fish bone on his GIT but due to absence of any serious symptoms, it was just ignored until the appearance of pain in the anal region on the 6th day. A detailed clinical history and physical examination are essential for the diagnosis and management of any lesions [8]. Acute peritonitis is frequently caused by perforation and presented as a sudden, severe abdominal pain due to sharp FBs. High fever develops rapidly with nausea, vomiting and paralytic ileus.

As the bacterial infection may spread to affect the peritoneum in general, the condition becomes serious and septic shock may develop. Proper investigations and appropriate management should be confirmed.

### Conflict of Interest

We declare that we have no conflict of interest.

### References

- 1 Matrella F, Lhuire M, Piardi T, Dokmak S, Bruno O, Maestraggi Q et al. Liver hilar abscesses secondary to gastrointestinal perforation by ingested fish bones: surgical management of two cases. *Hepatobiliary Surg Nutr.* 2014; 3(3):156 – 162.
- 2 Ichimiya I, Fujiyoshi T, Kurono Y, Mogi G. Multiple Foreign Bodies (Fish Bones) in the Esophagus and Rectum. *Auris Nasus Larynx.* 1988; 15(1) :51-55.
- 3 Choi Y, Kim G, Chansup C, Kim D, Kim D. Peritonitis with small bowel perforation caused by a fish bone in a healthy patient. *World J Gastroenterol.* 2014;14; 20(6): 1626–1629.
- 4 How to Get a Fishbone Out of Your Throat: <http://www.enkivillage.com/how-to-get-a-fish-bone-out-of-your-throat.html>
- 5 Goh, B.K., Chow, P.K., Quah, HM. et al. Perforation of the Gastrointestinal Tract Secondary to Ingestion of Foreign Bodies. *World J Surg.* 2006; 30: 372-377
- 6 Ng CM, Tsui KKD, Wong HH, Yau KK, Li M KW. Journals Case Report Sharp foreign body and ischio-rectal abscess Department of Surgery, Pamela Youde Nethersole Eastern Hospital, Hong Kong, China. *Int J Med Med Sci.*2010; 2(8):232-233.
- 7 Dugger K, Lebby T, Brus M, Sahgal S, Leikin JB. Hepatic abscess resulting from gastric perforation of a foreign object. *Am J Emerg Med.*1990; 8 (4):323-325
- 8 Alawi H, Mohammed AS, Faiyza H. Ingested Fish Bone, Unusual Cause of Perianal Sepsis, A Case Report Bahrain. *Med Bull.* 2001; 23(2): 98-99.